

Combination of Periodontic and Orthodontic in Treating Pathological Migration Systematic Review

by Sri 01

FILE	ODONTIC_IN_TREATING_PATHOLOGICAL_MIGRATION_SYSTEMATIC_REVIEW.PDF (301K)		
TIME SUBMITTED	02-NOV-2019 12:10PM (UTC+0700)	WORD COUNT	2908
SUBMISSION ID	1205415705	CHARACTER COUNT	17368

Combination of Periodontic and Orthodontic in Treating Pathological Migration: Systematic Review

Sri Oktawati^{1*}, Fatmawati M²

1. Department of Periodontology, Faculty of Dentistry, University of Hasanuddin, Makassar, Indonesia.
2. Postgraduate Professional Education Student of Department of Periodontology, Faculty of Dentistry, University of Hasanuddin, Makassar, Indonesia.

Abstract

The aim this study to see the difference in the success rate of a combination of periodontic-orthodontic treatments in treating pathological migration cases with and without periodontal surgery. A systemic review was performed to articles published from January 2005 to December 2017. An electronic database search within Wiley resulted 243 articles and 5 articles from PubMed, yet only 5 articles considered to meet the inclusion criteria. PRISMA guidelines and PICO question were used in this review. A total of 15 patients were treated with surgical techniques, and 2 patients with non-surgery techniques are included in the article. The combination of periodontic-orthodontic treatment with periodontal surgical techniques indicates a less period of treatment (between 6 to 19 months), yet those who did not perform periodontal surgery showed longer period of treatment (between 22 to 33 months). Combined orthodontic treatment improves periodontal conditions from the site of the damaged bone. Bone morphology altered by orthodontic treatment may improve the results of treatment guided tissue regeneration. This study confirms the possibility of a combined orthodontic periodontal approach that prevents periodontal tissue destruction and results in improved aesthetics as a result of rearrangement and increased papilla height. Compared to non-surgical therapy treatment, surgical therapy has a better result and usually heals faster.

Review (J Int Dent Med Res 2019; 12(2): 755-759)

Keywords: Orthodontic treatment, Periodontal treatment, Alveolar bone loss, Periodontitis, Tooth movement.

Received date: 16 October 2018

Accept date: 27 December 2018

Introduction

Pathological migration of the tooth is the movement due to disruption of the balance between the factors that maintain physiologically tooth position by periodontal disease. Periodontal disease causes loss of supporting structure. If the supporting structure maintaining the normal position of the tooth is disturbed by periodontal disease, the patient may experience pathological dental migration such as procline, diastema, rotation, extrusion and mobility of the teeth which cause teeth moving from actual position and misalignment of teeth as well as the occurrence of malocclusion. To restore the position of the

teeth in order to obtain normal occlusion, it is necessary to take orthodontic treatment and comprehensive periodontal treatment, which coordinates all treatment procedures to create a functioning tooth in a healthy periodontium environment.¹⁻⁵

The main plan for periodontal treatment consists of treatments with different goals for each patient according to their needs. The preparation of the main plan is based on diagnosis, the activity of the disease, as well as the indication of the selected treatment technique. The main goal of comprehensive treatment is the removal of gingival inflammation and correction of conditions that cause or aggravate inflammation. To achieve this goal, the first step is to remove the irritant on the root surface of the tooth, reduce the depth of the periodontal pocket, and then create a gingival contour and a conducive mucogingival relationship in maintaining the health of the periodontium. The patient's systemic condition needs to be evaluated, as the condition may affect the periodontal treatment plan in terms of the

*Corresponding author:

Sri Oktawati

Department of Periodontology

Faculty of Dentistry, University of Hasanuddin,

Makassar, Indonesia

E-mail: periounhas_sri@yahoo.com

periodontium response to treatment.⁶⁻⁸

For those reasons, the author tries to provide information on techniques that should be performed to deal with pathological migration problems by comparing different periodontal treatment techniques with or without periodontal surgery by focusing on the length of treatment for each technique for successful treatment in each case.

The aim of this paper is to review the difference in the success rate of a combination of periodontal-orthodontic treatment in treating pathological migration cases with and without periodontal surgery

Materials and methods

This systematic review was written according to the guidelines of PRISMA (Preferred Reporting Items for Systematic reviews and Meta-Analyses) for reporting studies evaluating healthcare interventions.¹

Population, Intervention, Control, Outcome question (PICO)² of the present systematic review was: is there any difference on the treatment time for both surgical and non-surgical techniques in combination of periodontic and orthodontic treatment in treating pathological migration? (Figure1).

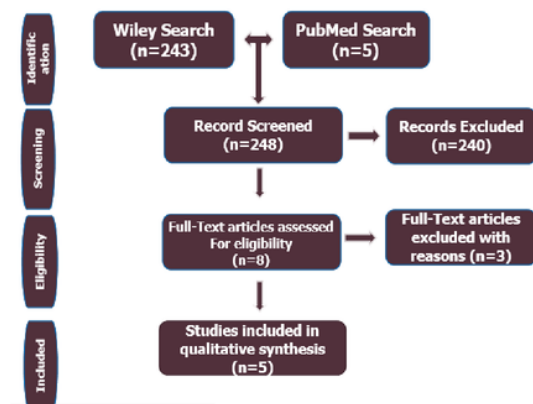


Figure 1. Preferred reporting items for systematic reviews and meta-analysis flow diagram.

Search strategy. Initial Pubmed and Wiley search of the English language literature were performed to establish a study protocol. The searches were conducted to identify articles published in dental journals from January 2005 to

December 2017 focusing on a combination of periodontic-orthodontic treatment in treating pathological migration cases with and without periodontal surgery. The MeSH keywords used were “orthodontic treatment”, “periodontal treatment”, “alveolar bone loss”, “periodontitis”, “tooth movement”. The electronic search was limited to the English language journal only, year of publication, and full-text availability. Manual searches of published full-text articles and related reviews were performed afterwards. There are 243 studies covered the focus of this study, however, only 5 studies met the full inclusion criteria. Specific keywords were used to identify the appropriate studies needs and followed the characteristics of PICO question.²

Eligibility Criteria; The inclusion criteria in this systematic review were the following:

1. Article published in English
2. Patients treated were received a combination of periodontal and orthodontic treatment.
3. Patients having pathological teeth migration of their anterior teeth
4. Any clinical study published between January 2005 to December 2017
5. Studies reporting patient having pathological tooth migration who received periodontal treatment with or without surgery
6. Studies included information about the duration of treatment starting from initial until the migration solved.
7. Studies included a clinical evaluation of the outcome with follow-up

The exclusion criteria were all studies which did not fulfil the above-mentioned criteria, such as animal studies and patient received only orthodontic or periodontal treatment alone.

Selections of Study; Specific keywords were used by two participating authors (FW and SO) resulted in the selection of the papers based on abstract and full-text reading. Independently, the two investigators selected the paper based on inclusion criteria formerly set. After that, all abstracts and full-texts were downloaded and individually evaluated. The eligibility criteria were used to identify the articles that will be used for this systematic review.

Extraction of Data; The data was retrieved by two reviewers (FW and SO) regarding the following parameters: year of publication; studies reported on a patient having pathological tooth migration who received periodontal treatment with or without surgery. All of the full-texts which met the inclusion criteria were read independently by two reviewers and evaluated to formulate this systematic review.

Results

The database search yielded 248 references, including 5 from PubMed and 243 from Wiley. The titles and abstracts were reviewed afterwards, and 1 studies were eligible for further analysis. The 5 full-texts which met the inclusion criteria were reviewed by the investigators. The flowchart of article selection is shown in Figure 1 with a total of 5 selected articles from initial yield of 248 studies by electronic literature search. After 248 titles of full-texts reviewed, 5 articles were selected for this systematic review inclusions, whereas the other 243 articles were excluded for reasons.

A total of 14 patients were treated with surgical techniques and 2 patients were reported to have non-surgical treatment (Table 1). The combination of periodontic-orthodontic treatment with periodontal surgical techniques indicates a length of treatment between 6 to 19 months, whereas those who did not perform periodontal surgery showed a length of treatment between 22 to 33 months. The median age of patients receiving a combination of periodontic-orthodontic treatment due to pathological dental migration was 22 years old.^{4,7,9,10}

Author/Year	Number of Patients	Age	Diagnosis	Treatment method	Treatment time
Feng Xingmei; Oba, Tomoko; Oba, Yasuo; Moriyama, Keiji.	1	56 years 6 months	Malocclusion Class I and Diastema Maxillary anterior region	Nonsurgical method	33 months
Pinho T, Neves M, Alves C	1	43 years	Chronic periodontitis Malocclusion Extrusi of the teeth	Nonsurgical and surgical methods	24 months
Xie Y, Zhao Q, Tan Z & Yang S	1	22 years 6 months	Malocclusion class I skeletal severe periodontitis and pathologic migration	Nonsurgical method	22 months
Ishihara Y, Tomikawa K, Deguchi T, Honjo T, Suzuki K, Kono T, Yamashiro T	1	22 years 6 months	Malocclusion angle class I, procline anterior teeth. Periodontitis	Periodontal Treatment 1 years. Then orthodontic treatment surgical, nonsurgical method	28 months
Cao T, Xu L, Shi J & Zhou Y	14	22-41 years	Migration and extrusion of maxillary anterior teeth. Chronic periodontics	the surgical method (GTR)	6-19 months

Table 1. Descriptive data from the 5 included studies that reported on combination of periodontic and orthodontic treatments for pathological migration.

Discussion

Pathological migration of teeth can be treated with a combination of periodontic-orthodontic treatment, either with non-surgical periodontic therapy or may be combined with surgical periodontic therapy. Several case reports show successful outcomes in periodontic-orthodontic combined therapy on pathological migration of teeth with repositioning.^{7,11} Before activating orthodontic treatment, periodontal therapy is performed, including periodontal flap surgery, by periodontitis, and usually during periodontal therapy, the patient has shown a decrease in pocket probing depth, sulcus bleeding, and increased attachment level. If enhancement after periodontal therapy has been achieved then orthodontic treatment may be initiated.^{12,13}

The orthodontic movement begins 2 weeks after non-surgical periodontal therapy and the surgery is performed 12 months after orthodontic movement. Furthermore, orthodontic combinations with periodontal regeneration surgery are performed to enhance the aesthetics and function of extruded maxillary incisors with deep infrabony defects and diastema. Successful results have been observed 7-10 days after periodontal therapy, and after a one year evaluation. Periodontal regeneration aims to reconstruct tissue damaged by periodontal disease, ie alveolar, cementum, and periodontal ligaments. Surgery is performed 12 months after orthodontic movement. Furthermore, orthodontic combinations with periodontal regeneration surgery are performed to enhance the aesthetics and function of the maxillary extruded deep intrabony defects and diastema. The orthodontic movement begins 2 weeks after the periodontal surgery. This combination of treatments indicates stable occlusion and aesthetic enhancement. The patient's periodontal status should be reevaluated by periodontitis after 6 to 8 weeks, no pockets more than 5 mm and orthodontic movements performed do not cause further damage to the periodontal tissues, plaque control and inflammatory elimination are essential during orthodontic treatment of patients with periodontal disease. In the corrective phase, orthodontist patients receive periodontal treatment periodically. After orthodontic treatment is declared complete, patients are asked to be reevaluated every 3 to 6 months to prevent re-

infection and recurrence.^{10,14-17}

If treatment of periodontal disease with non-surgical and surgical methods is selected, scaling and root planning should be performed in 2 sessions. Some researchers have concluded that orthodontic tooth movement may reduce probing depth, and improve bone healing. Intrusion may occur in patients with healthy periodontal status because it does not result in a decreased the marginal bone if gingival inflammation can be controlled. To get the best result, the force used 5-15 g/teeth.¹³

The procedure can rebuild bone and periodontal structures by increasing mesenchymal cells that will affect osteoinductive factors differentiated into cells that are able to regenerate periodontal structures. The likelihood of combined orthodontic-periodontic treatment is done to deal with pathological migration of teeth showing the elevated clinical and radiological parameters.^{10,18}

In 2015, Cao et al.¹⁰ treated 14 adults with a total of 56 elongated maxillary incisors with horizontal bone defects receiving orthodontic periodontal treatment with a circular supracrestal disorder. To improve bone morphology, periodontal regeneration and guided tissue regeneration were performed on anterior teeth with angular bone defects after orthodontic treatment. The orthodontic combined periodontal treatment improved the periodontal condition of the damaged bone. This suggests that combined orthodontic periodontal treatment improves periodontal conditions at the site of damaged bone. Bone morphology altered by orthodontic disorders with fibrotomy may improve subsequent guided tissue regeneration results. The orthodontic tooth movement that changes the horizontal bone defect into a narrower and deeper defect will increase regeneration of the periodontium through guided tissue regeneration. A combined regenerative orthodontic-periodontal surgical treatment, effective for patients with horizontal bone defects, shows significantly elevated alveolar bone height, an improved periodontal index and pathological dental migration treated with combined orthodontic-periodontic treatments. Surgical techniques result in a shorter treatment time of 16 to 22 months compared with non-surgical techniques that took longer.¹⁰

A study by Xie et al.⁷ in 2014 reported a 22-year-old man with severe periodontitis and

pathological tooth migration that was successfully treated with effective orthodontic therapy and a combination of periodontal treatments. After 22 months of orthodontic treatment, the occlusal trauma due to the pathologic migration of the teeth can be improved, occlusion becomes stable, and reduces the severity of periodontitis. This case report shows that alveolar bone resorption is preventable and that multidisciplinary orthodontic treatment of periodontal patients with pathologic migration without periodontal surgery is effective and helpful. After 22 months of treatment, stable occlusion was achieved and maintained for a period of time. Although the orthodontic treatment is complete, periodontitis maintenance is continued and care is maintained every 3 to 6 months to prevent infection and recurrence after the successful treatment. From this study, it can be concluded that orthodontic tooth movement can reduce probing depth, and improve bone damage.^{7,11,13}

Pinho et al.⁹ suggests numerous studies showing that orthodontic treatment may improve the periodontal situation in patients with pathologic migration proven to improve functional and aesthetic functioning after treatment. It is generally recommended that orthodontic treatment should be preceded by periodontal therapy, based on the belief that orthodontic treatment to inflammation may cause irreversible damage to the periodontium. Periodontal therapy of the corrective phase or pocket surgery should be completed before orthodontic therapy.⁹

Conclusions

Combined orthodontic treatment improves periodontal conditions from the site of the damaged bone. Bone morphology altered by orthodontic treatment may improve the results of treatment guided tissue regeneration. This study confirms the possibility of a combined orthodontic periodontal approach that prevents periodontal tissue destruction and results to improve aesthetics as a result of rearrangement and increased papilla height. Compared to non-surgical therapy treatment, surgical therapy has a better result and usually heals faster.

Declaration of Interest

The authors report no conflict of interest.

References

1. Moher D. The PRISMA Statement for Reporting Systematic Reviews and Meta-Analyses of Studies That Evaluate Health Care Interventions: Explanation and Elaboration. 2009;62(10).
2. Wallace BC, Kuiper J, Sharma A, Zhu M, Marshall IJ, Kuiper J. Extracting PICO Sentences from Clinical Trial Reports using Supervised Distant Supervision. *J Mach Learn Res.* 2016;17:1-25.
3. Brunsvold MA. Pathologic Tooth Migration. *J Periodontol.* 2005;76(6):859-66.
4. Ishihara Y, Tomikawa K, Deguchi T, et al. Interdisciplinary orthodontic treatment for a patient with generalized aggressive periodontitis: Assessment of IgG antibodies to identify type of periodontitis and correct timing of treatment. *Am J Orthod Dentofac Orthop.* 2015;147(6):766-80.
5. Santos Gusmão E, Deschamps R, De Queiroz C, et al. Association between malpositioned teeth and periodontal disease. *Dent Press J Orthod.* 2011;8716(4):87-94.
6. Shi J, Lin W, Li X, Zhang F, Hong X. Hereditary Gingival Fibromatosis: A Three-Generation Case and Pathogenic Mechanism Research on Progress of the Disease. *J Periodontol.* 2011;82(7):1089-95.
7. Xie Y, Zhao Q, Tan Z, Yang S. Orthodontic treatment in a periodontal patient with pathologic migration of anterior teeth. *Am J Orthod Dentofac Orthop.* 2014;145(5):685-93.
8. Karadas M, Cantekin K, Celikoglu M. Effects of orthodontic treatment with a fixed appliance on the caries experience of patients with high and low risk of caries. *J Dent Sci.* 2011;6(4):195-9.
9. Pinho T, Neves M, Alves C. Multidisciplinary management including periodontics, orthodontics, implants, and prosthetics for an adult. *Am J Orthod Dentofac Orthop.* 2012;142(2):235-45.
10. Cao T, Xu L, Shi J, Zhou Y. Combined orthodontic-periodontal treatment in periodontal patients with anteriorly displaced incisors. *Am J Orthod Dentofac Orthop.* 2015;148(5):805-13.
11. Keim RG. Aesthetics in clinical orthodontic-periodontic interactions. *Periodontol 2000.* 2001;27(20):59-71.
12. Wikesjö UME, Nilvéus RE, Selvig KA. Significance of Early Healing Events on Periodontal Repair: A Review. *J Periodontol.* 1992;63(3):158-165. doi:10.1902/jop.1992.63.3.158.
13. Baelum V, López R. Defining and predicting outcomes of non-surgical periodontal treatment: A 1-yr follow-up study. *Eur J Oral Sci.* 2016;124(1):33-44.
14. Danz JC, Bibby BM, Katsaros C, Stavropoulos A. Effects of facial tooth movement on the periodontium in rats: A comparison between conventional and low force. *J Clin Periodontol.* 2016;43(3):229-37.
15. Monea M, Moldovan C. Rare root morphology of a maxillary central incisor associated with gingival hyperplasia an endodontic case report. *Med (United States).* 2016;95(18):e3617.
16. De Lange GL, Overman JR, Farré-Guasch E, et al. A histomorphometric and micro-computed tomography study of bone regeneration in the maxillary sinus comparing biphasic calcium phosphate and deproteinized cancellous bovine bone in a human split-mouth model. *Oral Surg Oral Med Oral Pathol Oral Radiol.* 2014;117(1):8-22.
17. Zulfa L, Mustaqimah DN. Terapi periodontal non-bedah Non-surgical periodontal therapy. *J Dentomaxillofacial Sci.* 2011;10(1):41.
18. Scarfe WC, Azevedo B, Pinheiro LR, Priaminiarti M, Sales MAO. The emerging role of maxillofacial radiology in the diagnosis and management of patients with complex periodontitis. *Periodontol 2000.* 2017;74(1):116-39.

Combination of Periodontic and Orthodontic in Treating Pathological Migration Systematic Review

ORIGINALITY REPORT

%27
SIMILARITY INDEX

%10
INTERNET SOURCES

%21
PUBLICATIONS

%13
STUDENT PAPERS

MATCHED SOURCE



Submitted to Universitas Hasanuddin
Student Paper

%10

10%

★ Submitted to Universitas Hasanuddin
Student Paper

EXCLUDE QUOTES ON

EXCLUDE BIBLIOGRAPHY ON

EXCLUDE MATCHES < 5 WORDS